

## Brain Tumor Detection using Random Walk Solver Based Segmentation from MRI

Madhusudan B Kulkarni<sup>1</sup>, Dr.Channappa Bhyri<sup>2</sup>, Dr.Kalpana Vanjerkhede<sup>3</sup>

<sup>1</sup>PG Student, Department of Electronics and Instrumentation Engineering,

<sup>2,3</sup>Professor, Department of Electronics and Instrumentation Engineering,

Poojya Doddappa Appa College of Engineering, Kalaburagi, Karnataka, India

**Abstract-** This paper introduces a new algorithm which takes the gradient differential as specified criteria for identification and detection of brain tumors in magnetic resonance images. This algorithm eliminates the regions of Brain that doesn't matches the criteria of maximum spatial frequency, intensity since these are the two specified characteristics for finding the tumor part. The basic concepts of image processing are some noise removing functions such as median filter. At last by applying extension of maximal transformation and Regional transformation and by collecting the properties region wise we noticed the most specific part of tumor. Experimental results on several medical images containing brain tumor verifies that the proposed algorithm takes seconds on an average to detect the tumor part which is good when compared with existing methods.

**Index Terms-** Magnetic resonance imaging, spatial frequency, median filter, maxima transformation, regional transformation.

**1. INTRODUCTION:** In the past decades, a dynamically growth has been observed on brain cancer diagnosis in the multi-number research works. Most of the University centers are focusing on the topic because of the fact that the spreading disease in Brain cancer among the total world population. For Example 1: Tunisians, 14.8% of death among the elder people for the spread of Brain cancer. It is recorded as the second leading cause of death following the cardiovascular disease. Example 2: 3000 children are diagnosed with Brain tumor in US making it the most fatal cancer among children. Despite over all increasing in incidents and death, Brain cancer in the general of world population. The most likely to die of the disease is noted in Africa. The Brain tumor diseases involve a peak burden on economical of country and for the family a suffering of source and society because of the negative effects on affected people. Brain tumor is a localized intracranial lesion which occupies space within the skull and tends to cause a rise in intracranial pressure. However, benign tumor can press on sensitive areas of brain and cause very serious health problems. Unlike benign tumors in most other parts of the body, benign brain tumors are sometimes life threatening. Very rarely a benign brain tumor may become malignant. Classification of Brain tumors- Brain tumors can be benign or malignant.

**Benign brain tumor:** benign brain tumors do not contain cancer cells usually, benign tumors can be removed, and they seldom grow back. The border or edge of a benign brain tumor can be clearly seen. Cells from benign tumors do not invade tissues around them or spread to other parts of the body.

**A malignant brain tumor** is generally more serious and often is likely threatening. It may be primarily (the tumor originate from the brain tissue) or secondarily (metastasis from other tumor elsewhere in the body) they are likely to grow rapidly and invade the surroundings healthy brain tumor. Very rarely, cancer cells may break away from a malignant brain tumor and spread to spinal cord even to other parts of brain. Our research work (6) "detection of brain tumor, demarcation and quantification in medical images" gives information about the tumor detection and calculation of effected part where tumor exists but with a more efficient method. Detection of brain tumor is a burdensome work as it contains full automation in it. Identifying the mark and quantify the tumor portion for the machine, canonical as a human vision can discern. Brain tumor detection is an effortless task since it has a border of natural around it and roots of benign do not intense deep. Many image slices of a single brain develop when MRI is done. In only a few slices benign in nature will be seen because they do not go to the deeper part of the brain. These above criteria will discriminate the difference between the benign and malignant. To differentiate the abnormality part from normal part some paramount properties of the MRI image of the brain have to study.

**Methods used by Neurologist and Radiologist to detect the tumor-** to detect the tumor it takes two stages, tumor detection and screening method. Tumor detection: if any abnormal growth in the cell, which is uncontrolled, uncoordinated. Detection done initially through clinically (intracranial lesion) by two process. One is infectious and the other is mass lesion. Infectious is not a harmful part of the tumor. By applying clinically trials with Antibiotics (broad spectrum) or syrup culture sensitivity. By these infectious problem is solved. Mass lesion is a harmful part then we apply "screening method". Screening method is a detection of early cases in that Cancer Screening is the main weapon for early detection of a Cancer at a pre-invasive (in-situ) or pre-malignant stage. Effective Screening programs have been developed for Cervical Cancer; breast Cancer, oral Cancer and brain tumor etc. Cancer screening in the present knowledge, early detection and prompt treatment of early Cancer and precancerous conditions provides best possible protection against cancer for individuals. Cancer screening is possible because malignant disease is preceded for period of months/years by a pre-malignant lesion. Screening is performed by following three steps (a) Mass screening by comprehensive cancer detection examination, a rapid clinical examination by one or more body sites by a physician. (b) Mass screening at single sites: examination of breast, lung and oral cavity are the examples. (c) Selective screening refers to examination of those people thought to a special risk. Screening for chronic smokers for lung cancer is the example.CRI/MRI: mass lesion, investigations done through MRI with spectroscopy or position emission tomography (pet) for nuclear scan. By observing spots in the brain classify them as a malignant if it is a hot

spot otherwise it is benign, it is done through cutting some part of the organ and being studied under microscope (excision biopsy). During MRI the magnetic strength is 1.5 Tesla or above. It will take 30-45 minutes to detect through scanning.

**Demarcation and Quantification by Neurologist method** : a) extension and location of tumor part b) locating its size and shape c) studying the Morphology [ring/solid/cyst] d) in terms of numbers [single/multiple] e) verifying the presence of edema.

**2. RELATED WORK:** Tumor segmentation from magnetic resonance image (MRI) takes a Gradient Differential as specified criteria for identification and detection of brain tumor. Nobuyuki Otsu [1] to get maximum separable of gray levels as results the selection of discrimination criteria, which governs by optimal threshold. Michael R.Kaus et.al [2] the automatic algorithm allow the quick detection of brain tumor tissue with an accurate and reproduction comparative to those of manual segmentation. Lynn M. Fletcher-heath et.al [3] has presented the automated segment which has separated non-enhancement brain tumor size over time. Alian pitiot et.al [4] has presented “detecting demarking and quantifying using a hybrid approach “focused on the brain tumor detection in brain and also simplifying the affected area. Djamel Boukerroui et.al [5] a way to implement the method is performed using a wavelet i.e. decompose into sub-bands basis and can be used to processing 2D as well as 3D data. Kristin R.swanson et.al [6] adapted a boot strapping algorithm from which we could form a statistically reliable opinion on being limits of clinically observed data. Yuri Boykov et.al [7] the combinative optimized literature provides more min-cut/max-flow methods with different polynomial time complexity. Stuart S.C. Burnett et.al [8] illustrate the method by applying it the spinal canal. Segmentation is performed in three steps: (a) partial delineation (b)a deformable-model (c) original shape into its final position. Weibei Dou et.al [9] proposed a fuzzy model describing the characteristics of tumor, the fusion based on fuzzy fusion operators and the adjustment by the fuzzy region growing based on fuzzy connection. Kyungsuk (PETER) pyun et.al [10] HMGMS incorporate supervised learning, fitting the observation probability distribution given by each class by a gauss mixture estimated using vector quantization. Hassan Khotanlou et.al [11] has proposed a detection process is based on selecting asymmetric areas with respect to the approximation brain symmetry plane. Jason J.Corso et.al [12] the main contribution of these paper is a Bayesian formulation for incorporating soft model assignments into the calculation of affinities, which is conventionally model free. T.Logeswari et.al [13] a clustering based approach using a self organizing map (SOM) algorithm is proposed for medical image segmentation. Sufyan y.Ababneh et.al [14] the segmentation algorithm includes a novel content- based, two pass disjoint block discovery mechanism, which is design to support automation. P.Narendran et.al [15] proposed an original and new method that combines region and boundary information in two phases: initialization and refinement.

**3. PROPOSED METHOD:** In this paper the proposed algorithm describes the method of using spatial frequency for combining the image modeling techniques, extension of maximal transformation and regional maximal transformation.

**Step 1:** We know Image can be seen clearly in gray scale. So Read and convert the Image from RGB to gray scale. A data arranged in the form of matrix representation is an Image or digital Image. For reading the Image the mat lab command is imread. This command read image from the graphic files. Next step is the conversation of grayscale since the conversation can be done by two methods. (a) Average method (b) Weighted method .Average method is the average of three colors (Red, green and blue). By applying average method the image converts into the gray scale and the Image will be in the black. This problem arises due to the average of the red, green and blue. These three colors have their different wavelengths while forming an image and they contribute in their own fashion. To avoid these turning of black Image it can be overcome by weighted method. We know that wavelength of red color is greater than the remaining two components of the remaining colors. And the Soothing Effect to the eyes is given by the green color. The wavelength of green color is lesser than that of red color. It defines that by decreasing the significance of red color there will be enhancement in the green color .The wavelength of blue color is adjusted between red and green and these gives the new equation.

New gray scale image=  $((0.3 * R) + (0.59 * G) + (0.11 * B))$ .

By following the above equation percentage of red color is 33%, green is 59% and the blue is 11%.

**Step 2: Preprocessing Steps:** By applying the median filter there will be suppression of noise and removal of noise, it also preserve the edges of the image which is the main framework in our work. Due to its criteria of storing the edges during smoothing, de-noising method has helped in securing the services of Information. It behaves like a non-linear operator. In according to their Intensity or entropy values the pixels are arranged in a local window by a non-linear operator. At last results show that the value of the pixels replaces the middle value in their specific order.

**Step 3: Grayscale Contrast enhancement:** In medical images, in enriching the quality. Process of contrast enhancement plays a very important role. To clean up the unwanted noise, enhancing the image brightness and contrast it has with contrast enhancement techniques finally the result shows that it provides clear and free from unwanted noise, easy to understand and to look for diseases under screening process by the doctors. The Intensities of grayscale image function ‘imadjust’ of matlab is used for contrast enhancement. This function creates a gamma function. By the gamma function the curve of component of grayscale towards giving out and filled with light up the intensity (if  $\gamma < 1$ ). On the other hand it would be depressing and groom up the intensity for the pixels (if  $\gamma > 1$ ). Gamma is a very good characteristic for almost entire systems of digital

image. Gamma gives typical association of pixels of numeric values and its luminance (giving off light especially in the dark). Suppose if gamma is ignored, the image cannot be seen clearly by our eyes on a standard monitor. We called this technique as gamma correction, gamma compression or Gamma coding. The expression of power-law is

$$V_{out}=AV_{in}^{\gamma} \dots\dots\dots (1)$$

**Step 4:** Divide the whole image into four quadrants in such a way that four quadrants are divided equally and then calculate maximum and minimum values of pixels for each quadrant. After dividing an MRI (magnetic resonance image) into 4 equal quadrants. Note and calculate the basic properties spatial frequency (overall activity level of an image) and intensity (peak value of pixels) for each quadrant separately. By dividing these we can concentrate and work only on one quadrant out of four quadrants where there is possession of tumor. Spatial frequency is written by the following equation

$$SF = \sqrt{(RF)^2 + (CF)^2} \dots\dots\dots (2)$$

where RF and CF are row frequency and column frequency respectively.

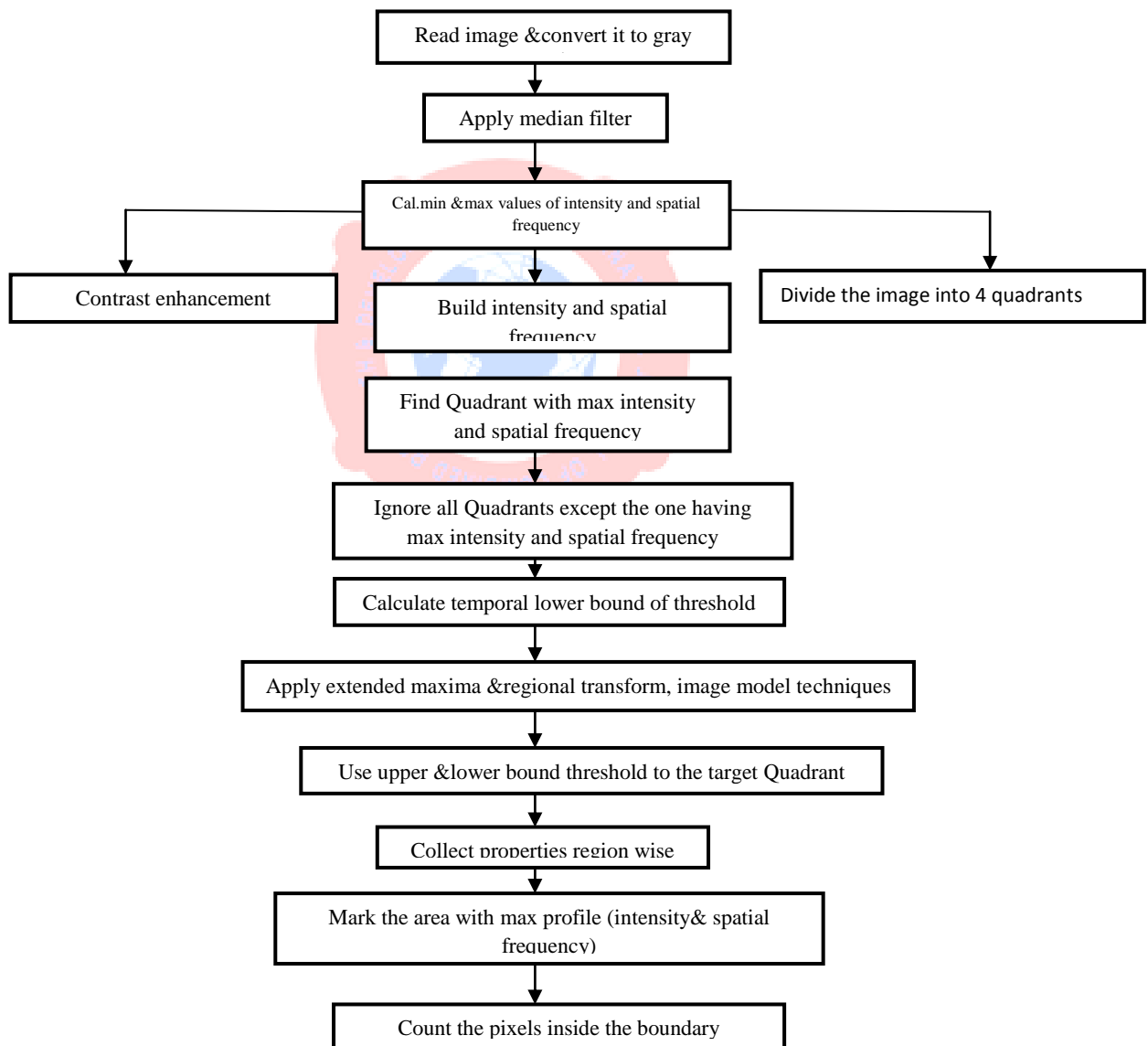


Fig.1 Block diagram of proposed method for brain tumor images

**Step 5:** By detail examination and analyzing the two characters i.e. intensity and spatial frequency we have to build the matrix then according to their pixel values by selecting the quadrant which is having the maximum intensity and spatial frequency values we need to ignore other quadrants which do not match the maximum intensity and spatial frequency values. Since these two parameters should always maximum in finding the tumor portion in the image as in relation to other parts of the image.

**Step 6:** A temporal lower bound of threshold is applied to general image models of observations in which it make worse of blur (becomes less distinct), signal dependent and noise of independent signals, and nonlinear of sensor is derived. And by calculating temporal lower bound of threshold (a level or point marking the start) and using lower-upper bound threshold to the required quadrant. For any unbiased image restoration, lower bound on average mean square errors scheme is derived. It is expressed in detail as a function of degradation parameters of image systems then we apply to calculate the values of lower bound and upper bound of threshold to the target quadrant.

**Step 7: Applying extension of maximal transformation, regional maximal transformation:** By applying these transformation we get the maximum of a function i.e. intensity range represents the tumor, which collectively known as extrema. Therefore we get the largest value within a given neighborhood quadrant which is a local or relative extrema. Finally by the application of regional maxima where the connected components of pixels with a constant value of intensity, whose external boundary pixels have a lower value that do not show the part of the tumor. All these transformations are applied on the image model of the test image.

**Step 8: Run Region Properties:** We need to study the properties of a particular connected of pixels to identify it. The big task is to determine the tumor present in human brain where it is considered as a connected component. To verify the tumor there we need to apply region props commands of matlab over that portion which is within the information solidity and it is known as convexity property of the region. Solidity can be defined as the ratio of an object and some other enclosing container. These properties specify the portion of the pixels which includes within the region and also in the convex hull. This property supports only 2-D input label matrices. It is simplified as area or convex area. Solidity is a complex, but probably a good distinguisher among the cells with the projections or uneven shape V/s round cells generally seen with in the region.

**Step 9:** The area is marked within a boundary that matches to maximum profile. By this, the tumor portion is detected within the boundary and it is been built up so that the tumor can be clearly visible and understood and differentiated by the viewer.

**Step 10: The pixels are counted which lie inside the boundary:** Finally the tumor portion has been detected, demarcated and calculated. By counting the no. of pixels it has to be quantified and specifies the tumor area that lies within the border region.

#### 4. EXPERIMENTAL RESULTS:

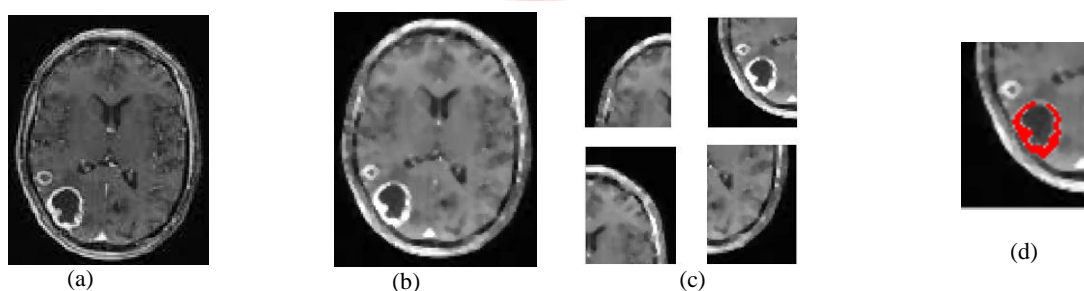


Fig.2. a) Image with brain tumor b) Enhanced image c) Four quadrants image d) Tumor region in third quadrant

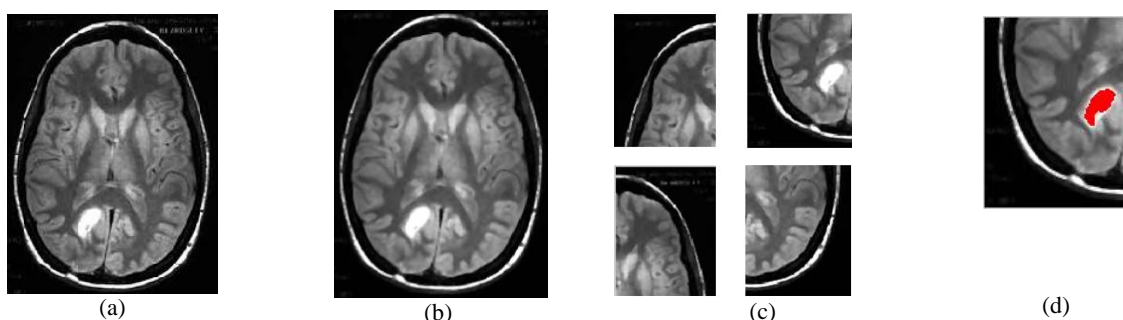


Fig.3. a) Image with brain tumor b) Enhanced image c) Four quadrants image d) Tumor region in third quadrant

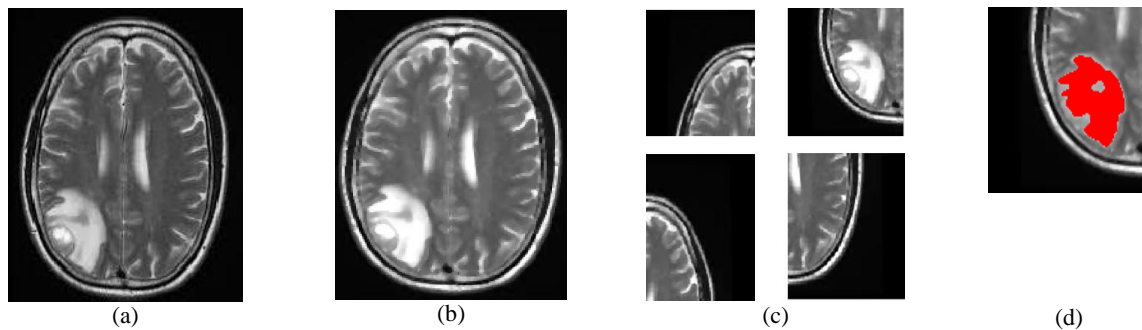


Fig.4. a) Image with brain tumor b) Enhanced image c) Four quadrants image d) Tumor region in third quadrant

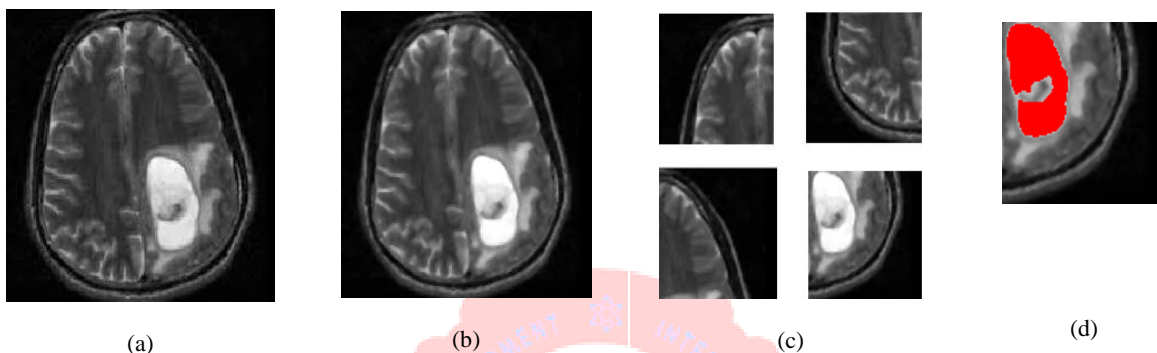


Fig.5. a) Image with brain tumor b) Enhanced image c) Four quadrants image d) Tumor region in fourth quadrant

**Table 1: Results for four different cases containing brain tumor**

Figure No.	Tumor Quadrant	Spatial Frequency (SF)	Tumor size (in pixels)	Entropy Execution Time (in seconds)
Fig.1	Quadrant 3	0.0082	130	<b>0.2349</b>
Fig.2	Quadrant 3	0.0279	389	<b>0.5334</b>
Fig.3	Quadrant 3	0.2150	1339	<b>0.6439</b>
Fig.4	Quadrant 4	0.0795	1567	<b>0.5308</b>

## 5. CONCLUSIONS:

The proposed method is much more better especially the execution time has been reduced. Moreover rather than working on the whole image for the pixels of tumor portion, the proposed algorithm is applied only to that quadrant where there is necessity and possibility of spatial frequency, intensity and solidity matrix and transformation of image. By this way it has reduced the calculation part. For Future Scope, it could be suggested that one can take advantage of machine learning non parameterized algorithm that user's regression decision tree to arrive at the classification of objects like tumor and non-tumor parts.

## 6. REFERENCES:

- [1] Nobuyuki Otsu, "A Threshold Selection Method from Gray -Level Histograms", IEEE Transactions on systems, Man and Cybernetics, Vol.SMC-9, No.1, January 1979.
- [2] Michael R. Kaus, Simon K.Warfield, Arya Nabavi, Peter M.Black, Ferenc A. Jolesz, Ron Kikinis, "Augmented Segmentation of MR Images of Brain Tumors" Radiology; 218:586-591,magnetic resonance (MR), Volume measurement, 10.121412, 10.12143, 2001.



- [3] Lynn M. Fletcher-Heath, Lawrence O. Halla, Dmitry B. Goldgof, F. Reed Murtagh, "Automatic segmentation of non-enhancing brain tumors in magnetic resonance images" *Artificial Intelligence in Medicine* 21: 43-63, Elsevier Science B.V., 2001.
- [4] Alain Pitiot, A.W. Toga, P.M. Thompson, "Adaptive elastic segmentation of brain MRI via shape-model-guided evolutionary programming" *IEEE Transactions on Medical Imaging*, Vol.: 21, Issue: 8, Aug. 2002.
- [5].T.Tirupal, B.Chandra Mohan, "Pixel-Level Multifocus Image Fusion based on Wavelet Transform & Principal Component Analysis" *Journal of Innovation in Electronics & Communication*, JIEC-2012, vol.2, Issue 2, ISSN: 2249-9946, pp.60-64.
- [6] DjamalBoukerroui, AtillaBaskurt,J.Alison Noble, Olivier Basset, "Segmentation of ultrasound images—multiresolution 2D and 3D algorithm based on global and local statistics" *Elsevier Science B.V*,Vol. 24, Issues 4–5, February 2003.
- [7] Kristin R. Swanson, Carly Bridge, J.D. Murray, Ellsworth C. Alvord Jr, "Virtual and real brain tumors: using mathematical modeling to quantify glioma growth and invasion" *Elsevier B.V*,Vol. 216, Issue 1, 15 December 2003.
- [8] Yuri Boykov, Vladimir Kolmogorov, "An Experimental Comparison of Min-Cut/Max-Flow Algorithms for Energy Minimization in Vision" *IEEE Transactions on Pattern Analysis and Machine Intelligence*, Vol. 26, No. 9, September 2004.
- [9] Stuart S. C. Burnett, George Starkschall, Craig W. Stevens,Zhongxing Liao, "A deformable-model approach to semi-automatic segmentation of CT images demonstrated by application to the spinal canal" *The International Journal of Medical Physics Research and Practice, Medical Physics* 31, 251 (2004), 22 January 2004.
- [10] Weibei Dou, Su Ruan, Yanping Chen, Daniel Bloyet, Jean-Marc Constans, "A framework of fuzzy information fusion for the segmentation of brain tumor tissues on MR images" *Elsevier B.V*,Vol. 25, Issue 2, 2006.
- [11] Kyungsuk (Peter) Pyun, Johan Lim, Chee Sun Won, Robert M. Gray, "Image Segmentation Using Hidden Markov Gauss Mixture Models" *IEEE Transactions on Image Processing*, Vol. 16, No. 7, July 2007.
- [12] Hassan Khotanlou, Olivier Colliot, Isabelle Bloch "Automatic brain tumor segmentation using symmetry analysis and deformable models" *Bu Ali Sina University and Paristechile de France*, 2008.
- [13] Jason J. Corso, Eitan Sharon, ShishirDube, Suzie El-Saden, Usha Sinha, Alan Yuille, "Efficient Multilevel Brain Tumor Segmentation With Integrated Bayesian Model Classification" *IEEE Transactions on Medical Imaging*, Vol. 27, No. 5, May 2008.
- [14].T.Tirupal, B.Chandra Mohan, S.Srinivas Kumar, "Multifocus Medical Image Fusion based on Fractional Lower Order Moments and Modified Spatial Frequency" *International Conference on Advances in Biotechnology, BIOTECH-2015, IITKANPUR, India*, ISSN: 2251-2489, 13-15 March 2015, pp.145-154.
- [15] T. Logeswari, M. Karnan, "An improved implementation of brain tumor detection using segmentation based on soft computing" *Journal of Cancer Research and Experimental Oncology* Vol. 2(1) pp. 006-014, March, 2010.
- [16] Sufyan Y. Ababneh, Jeff W. Prescott, Metin N. Gurcan, "Automatic graph-cut based segmentation of bones from knee magnetic resonance images for osteoarthritis research" *Elsevier B.V*,Vol. 15, Issue 4, August 2011.
- [17] P. Narendran, Mr. V.K. Narendira Kumar, Dr. K. Somasundaram, "3D Brain Tumors and Internal Brain Structures Segmentation in MR Images" *I.J. Image, Graphics and Signal Processing*, 1, 35-43, February 2012.
- [18] Sudipta Roy, Samir K. Bandyopadhyay "Detection and Quantification of Brain Tumor from MRI of Brain and it's Symmetric Analysis" *International Journal of Information and Communication Technology Research*, Vol. 2 No. 6, June 2012.
- [19] Mukesh Kumar, Kamal K.Mehta "A Texture based Tumor detection and automatic Segmentation using Seeded Region Growing Method" *International Journal of Computer Technology and Applications*,Vol 2 (4), 855-859, August 2011.
- [20] Ngah, U. K., Ooi, T. H., Sulaiman, S. N. &Venkatachalam, P. A. (2002). Embedded Enhancement Image Processing Techniques on A Demarcated Seed Based Grown Region. *Proc. of Kuala Lumpur Int. Conf. on Biomedical Engineering*. 170-172.
- [21] Lim, E. E., Venkatachalam, P. A., Ngah, U. K. & Khalid, N. E. A. (1999). "Liver Disease Diagnosis by Region Growing". *Proceedings of International Conference on Robotics, Vision and Parallel Processing for Automation*. 1. 38-45.
- [22] Khalid, N. E. A., Venkatachalam, P. A. & Ngah, U. K. (1999). "Diagnosis of Bone Lesion Based on Histogram Equalization". *Proceedings of International Conference on Robotics, Vision and Parallel Processing for Automation*. 1. 91-96.
- [23].T.Tirupal, B.Chandra Mohan, S.Srinivas Kumar, "Image Fusion of Natural, Satellite, and Medical Images using Undecimated Discrete Wavelet Transform and Contrast Visibility" *'National Conference on Recent Advances in Electronics & Computer Engineering', RAECE-2015, IITRoorkee, India*, 13-15 February 2015.